

Tracing the Blood Flow Direction of the Angular Artery and Vein by Color Doppler Ultrasonography

Gertrude M. Beer^{1*}, Bitschnau R² and Manestar M¹

¹Institute of Anatomy, Department of Macroscopic Anatomy, University Zurich, Irchel, Winterthurerstrasse 190, CH 8057 Zurich, Switzerland

²Institute of Internal Medicine and Angiology, Ausserlitzstrasse 71, A 6780 Schruns, Austria

Received Date: : April 06, 2016, Accepted Date: May 09, 2016, Published Date: May 19, 2016.

*Corresponding author: Gertrude M. Beer, Institute of Anatomy, Department of Macroscopic Anatomy, University Zurich, Irchel, Winterthurerstrasse 190, CH 8057 Zurich, Switzerland, Tel: 0041-442-020-400; Fax: 0041-442-020-410; E-mail: gertrude.beer@access.uzh.ch

Abstract

Whether the angular artery is the continuation of the facial or the ophthalmic artery has been a matter of debate. In the case that the angular artery is the continuation of the facial artery, the blood flow runs upward from caudal to cranial. On the other hand, when the angular artery is the continuation of the ophthalmic artery, the blood flow runs in the reverse direction. We sought an uncomplicated, non-invasive and reliable method to detect angular vessels and trace the direction of their blood flow.

Thirteen adult volunteers of both genders were included in the study. The patients were healthy individuals between 20 and 60 years of age. The examination and imaging of the angular artery was performed using a color Doppler ultrasound. The angular artery was present in all cases on the right side but absent in three cases on the left side. The source of the angular artery was the facial artery in eight cases on the right side and six cases on the left side. In all other cases, the source of the angular artery was the ophthalmic artery. An angular vein was always present but not running concomitant to the artery in seven cases. When the facial artery was compressed at the mandibular border, the flow persisted only in those angular arteries that arose from the ophthalmic artery with the exception of one case involving both sides.

Our study revealed that color Doppler ultrasonography is a non-invasive and reliable method for detecting the angular artery and vein and determining the direction of their blood flow. Thus, color Doppler ultrasonography is an uncomplicated method for adequate planning of axial nasolabial and other axial angular artery flaps even in real time before or during surgery.

Keywords: Angular Artery; Blood Flow Direction; Facial Reconstructive Surgery; Nasolabial Flap; Ophthalmic Artery; Color Doppler Ultrasonography

Introduction

The facial artery - the commonly assumed source of the angular artery - arises from the external carotid artery on the neck and takes a cranial and medial course. Reaching the lower border of the mandible, the facial artery hooks around the anterior edge of the masseter muscle and enters the face. On the face, the facial artery passes forward and upward across the buccinator muscle, almost up to the angle of the mouth. The facial artery then ascends at the side of the nose and ends at the medial palpebral commissure of the eye to anastomose with the dorsal nasal branch of the ophthalmic artery [1]. This terminal portion of the facial artery is mostly termed the angular artery and lies variably beneath or within the oral levator muscle (Figure 1). However, the facial artery occasionally ends by forming the submental artery, extends only as high as the angle of the mouth or the nose and finds no continuation as angular artery [1]. This deficiency is typically compensated by enlargement of one of the neighboring arteries. The angular artery is then mostly nourished by the dorsal nasal branch of the ophthalmic artery [2]. In anatomical dissections on 11 cadavers, Dagregorio, et al [3],

found the angular artery in continuity with the facial artery in only 8% of cases. In the other 92% of cases, the angular artery was in continuity with the ophthalmic artery. In addition, in a study of 50 French cadaver dissections, Mitz V, et al [4] reported that only 4% of the cases exhibit the classical continuation from the facial artery into the angular artery.

In the case that the angular artery is the continuation of the facial artery, the blood flow runs upward from caudal to cranial. On the other hand, when the angular artery is the continuation of the ophthalmic artery, the blood flow runs in the reverse direction.

Given that the angular artery is considered the basis for the axial nasolabial flap and a variety of other regional axial flaps, the direction of its blood flow is of major clinical importance for adequate flap design and the prevention of eventual flap necrosis.

To trace the presence of the angular artery and the direction of its blood flow, we sought to identify an uncomplicated, non-invasive and reliable method that is available in real time, before or even during surgery.

Methods

Thirteen adult volunteers of both genders were included in the study. The patients were healthy individuals between 20 and 60 years of age. The participants were recruited from an outpatient institute of internal and vascular medicine. The examination and imaging of the angular artery was performed using the color Doppler ultrasound Acuson X 300 (Siemens Healthcare Zentrale, 91052 Erlangen, Deutschland) with a VF 10-5 MHz transducer.

Informed consent was obtained from all participants according to the Helsinki declaration. Patients with previous operations in the face near the course of the facial and angular artery or patients with vascular pathologies and malformations were excluded. After applying ultrasonic contact gel, the presence of the angular artery and vein were investigated with the patient in a reclined position, and a possible concomitant course of the angular vein to the artery and the symmetry of the course of the vessels on the right and left side of the face were recorded. The transducer probe was moved from the mandible to the oral commissure and further cranial up to the medial palpebral ligament. Then, finger pressure was applied to the lower border of the mandible to prevent possible blood flow upward in the facial artery. The reversed flow in the angular artery was observed as a change in the displayed color of the vessels and in the waveform analysis.

The direction of the blood flow of the angular artery on each side was traced at the height of the alar base and the height of the medial palpebral ligament, and the flow diameter of the artery was recorded. All images were recorded on a photograph at the mentioned locations.

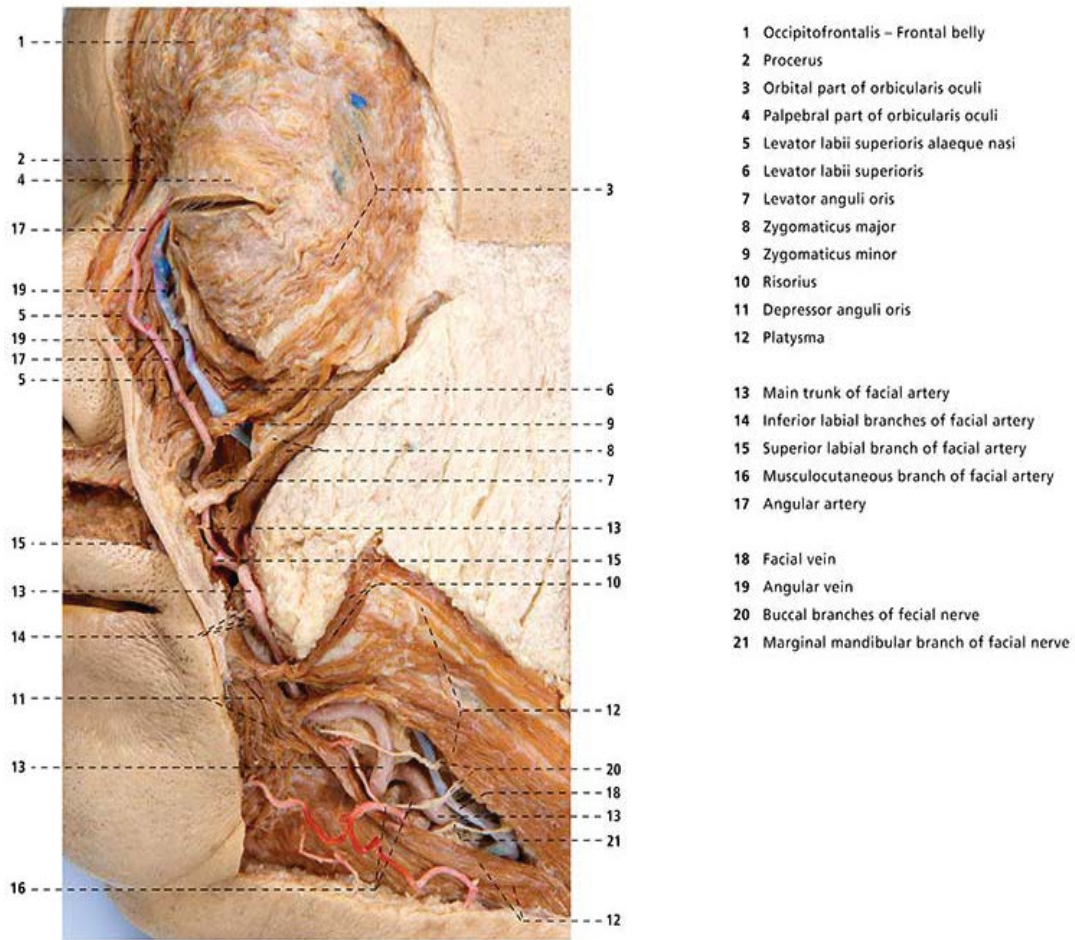


Figure 1: Anatomical situs of a left facial half with the angular artery (red) and vein (blue). In this case, the angular vessels are a direct continuation of the facial vessels.

Statistical analysis was performed by version 15 SPSS (SPSS, Inc., Chicago, IL, USA). Variables were expressed as frequency and percentage in the case of qualitative data and as mean value ± standard deviation in the case of quantitative data.

Results

The subjects were six men ranging in age from 54 to 60 years (mean 56 ± 4 years) and seven women ranging in age from 23 to 59 years (mean 50 ± 13 years).

Using the ultrasound Acuson X 300 with the VF 10-5 MHz transducer, the presence of the angular vessels, their direction of flow and the diameter of the artery were reliably detectable.

The angular artery was present and clearly visualized in all cases on the right side but absent on the left side in three cases (Figure 2).

At least one angular vein was present in seven cases on the right side and five cases on the left side (Figure 3). Concerning the positional relationship of the angular vein, it took a parallel, concomitant course to the artery in only five cases on both sides. In the remainder of cases, the vein was variably apart and always located further laterally.

Symmetry between the two facial halves concerning the course of the angular artery was detected in eight cases, and symmetry concerning the angular vein was noted in six cases.

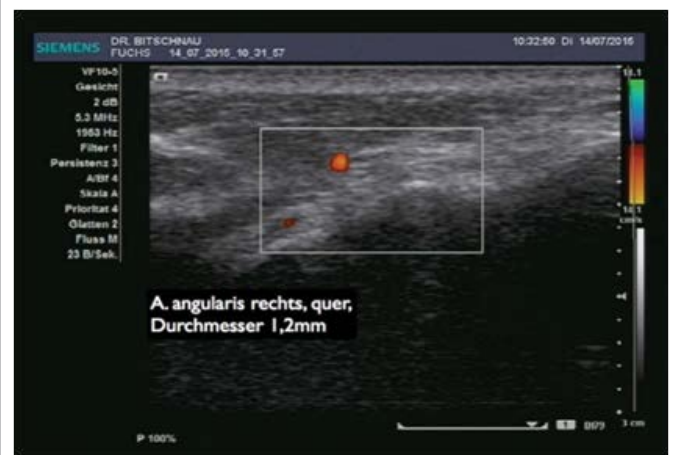

Figure 2: Color Doppler sonography. The angular artery at the height of the nasoalar region, horizontal direction, double cut. The diameter is 1.2 mm. The red color is coded as flow away from the transducer array, thus indicating cranial flow in the angular artery from the facial artery.

The source of the angular artery was the facial artery in eight cases on the right side and six cases on the left side (Figure 4 A, B). In all other cases, the source of the angular artery was the ophthalmic artery; however, in three cases, no angular artery was detectable

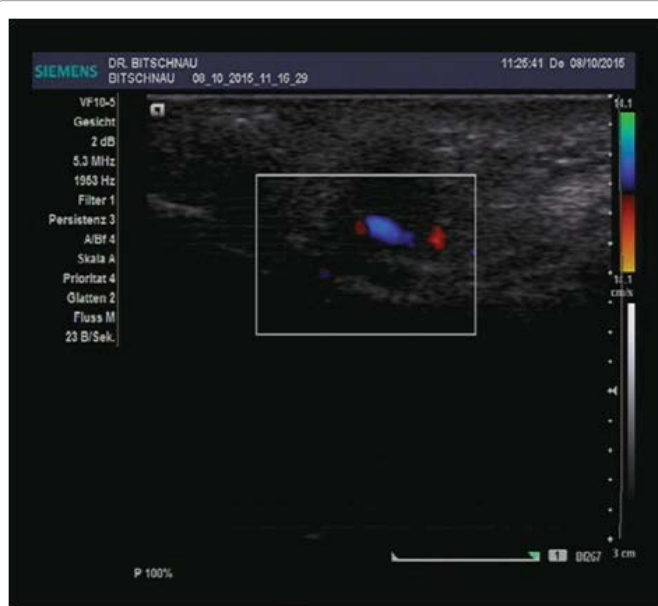


Figure 3: Color - coded duplex sonography. The angular artery is colored blue and accompanied by paired veins in the near vicinity that are colored red. The scale below is in mm.

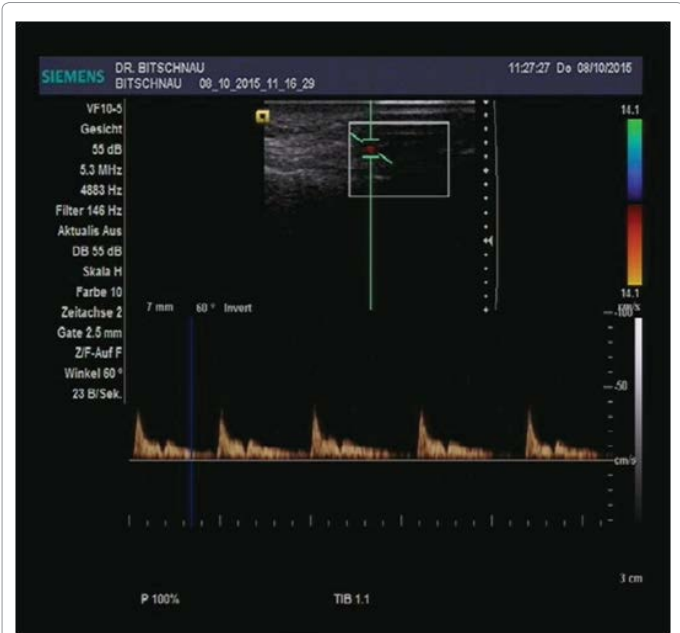

Figure 4B: Color - coded duplex sonography. The angular artery is colored in red. The direction of the flow moves toward the probe from the ophthalmic to the angular artery. The corresponding pulsed-wave Doppler signal is presented at the bottom.

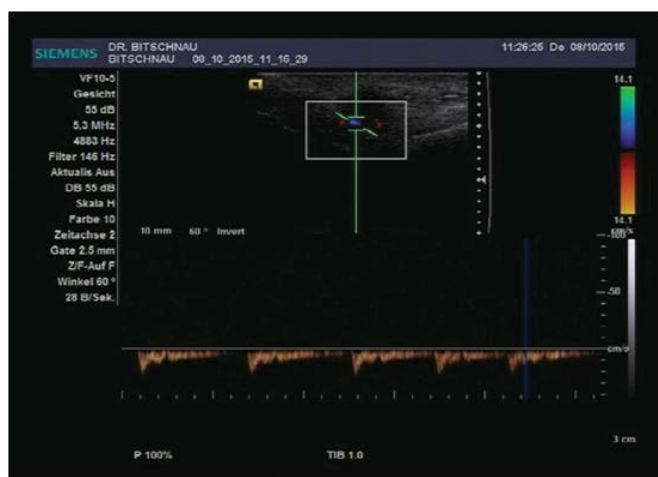


Figure 4A: Color - coded duplex sonography. The angular artery is colored in blue. The direction of the flow moves away from the probe from the facial to the angular artery. The veins with a flow in the opposite direction are colored in red. The reversed pulsed-wave Doppler signal is recorded at the bottom.

on the left side. When the facial artery was compressed at the mandibular border, the flow persisted in all angular arteries that arose from the ophthalmic artery with the exception of one case involving both sides.

The flow diameter of the angular artery when present was 1.5 ± 0.3 mm on the right side and 1.4 ± 0.7 mm on the left side at the height of the nasal base. At the height of the medial canthal ligament, the diameter was 1.1 ± 0.5 mm on the right side and 1.7 ± 0.7 mm on the left side.

Discussion

The study revealed that color Doppler ultrasonography can be used to detect the presence of the angular artery and vein and the direction of their blood flow. This finding is a prerequisite

for the planning of large axial flaps. The most famous of these flaps is the nasolabial flap. This flap was first described by Blasius in 1842 [3] and was reshaped by Tessier [3] in 1960. The nasolabial flap has been widely used as local flap for the coverage of small defects localized on the nose and near this region [5]. However, in most of these nasolabial flap designs, regardless of whether they are cranially or caudally based, these small flaps exclusively consist of skin and a variably thick layer of subcutaneous fat. Thus, these flaps do not contain the facial, angular or the ophthalmic artery and are instead random pattern cutaneous flaps. Although the vasculature of such flaps is technically random, Hynes B, et al [6], used angiographic examinations on cadavers to demonstrate that the small vessels of the subdermal plexus are generally oriented along its long axis, thus giving the flap a degree of axiality. He believed that this vascular orientation was the reason why such flaps are reliable in a one-staged repair [6,7]. However, the subcutaneous arterial network, its anastomotic connections and its axial orientation that mirrors the deeper lying angular artery are responsible for the reliability of its blood supply. Despite this assumption, other surgeons believe that the nasolabial flap must be delayed before a final successful transfer when its vascular supply is in doubt or the flap is distally pedicled [8]. However, these observations apply only to small and very small nasolabial flaps.

Generally, the naming of a specific vessel (e.g., the angular artery) suggests that the flap has a true axial blood supply and contains axial vessels. Publications on large, truly axial nasolabial flaps containing the angular artery have only recently been published [3,9]. In such huge flap designs measuring up to 10×5 cm, it is mandatory to include the angular vessels and to know the direction of the blood flow in advance to prevent tip necrosis or even complete flap failure.

The tendency for surgeons to attribute the blood supply of the nasolabial flap exclusively and automatically to the angular artery as a continuation of the facial artery may have been the reason for misconceptions about its vascularity and flap failures in such huge flaps. However, given the numerous variations of the facial

and angular artery, considerable confusion remains regarding the nature of its blood supply, especially for inferiorly based flaps.

Therefore, various proposals of categorization of the angular arterial origin into different types were published. In a study on 11 cadavers (22 hemifaces), Hou D, et al [10], reported that the course of the angular artery along the nasojugal fold was constant and defined four different types. In type I, the angular artery originates at the terminal branch of the facial artery (31.8%). In type II, the angular artery originates from the ophthalmic artery (51.9%). In type III, the angular artery is an anastomosis consisting of the terminal branch of the facial artery and the branch of the dorsal nasal artery (4.5%). In type IV, the angular artery originates from the infraorbital artery (4.5%). Using color Doppler ultrasonography, we only identified type I and II angular arteries.

Equally important is the examination of the angular vein and its localization by imaging. Zhao Z, et al and Zhao YP, et al [11,12] found that the location of the facial vein is not constant and that the facial vein is occasionally located apart from the artery with variable distances up to 22 mm and variable sizes. We made the same observation. In our cases where the vein did not accompany the artery, the artery was always situated laterally from the vein, thus making the usage of the nasolabial flaps somewhat difficult and less practical. Therefore, the detection of the divergence of the angular vein from the angular artery by ultrasound is important information for the planning of an axial pattern flap.

In general, color Doppler ultrasonography has replaced more invasive, time-consuming and expensive methods of identifying small vessels. Computed tomography and magnetic resonance angiography have been frequently used; however, the drawbacks of these methods include complexity of use, exposure to radiation and potential complications associated with the use of a contrast medium [12]. Color Doppler sonography has been predominantly used to prove the existence of vessels and the patency of flow. In addition, given ongoing technical improvements, this technique can identify even the smallest vessels. Shintani, et al [13], presented anatomically reliable locations of the tiny digital artery perforators in all ulnar and radial arteries of the fingers. For this examination, he used a Doppler with a high frequency probe (8 - 18 MHz). For angular vessels that are considerably larger than digital artery perforators, our Doppler probe with 10 to 15 MHz proved sufficient. Due to these properties, color Doppler sonography has also been introduced into the field of microsurgical free tissue transfer to construct new and reliable free fasciocutaneous flaps and define free flap territories based on a large solitary perforator. Doppler flow images are additionally used in postsurgical monitoring of free flaps.

One disadvantage of Doppler sonography is its analysis reproducibility. In addition, in the case of facial vessels, the tortuous character of the vessels can make visualization more difficult. Regarding facial and the angular vessel imaging, numerous reports have been published; however, the direction of the blood flow in vessels is rarely mentioned. Concerning the direction of blood flow in the angular artery, only general remarks were found in the literature. In a corresponding study, Zhao Z, et al [11] stated that it was not possible to evaluate artery size and the direction of blood flow using Doppler sonography. Additionally, he noted a very limited ability to detect veins. However, he noticed that reverse blood flow was detected in the angular artery after facial artery blood flow was stopped by applying manual pressure at the lower border of the mandible. This observation was reported in 12 volunteer adults using a 12-MHz linear-array transducer. The reversed blood flow in the facial artery was observed based on a change in the displayed color of the vessel and waveform analysis.

In the same manner, Zhao also observed the reversed blood flow of the facial artery at the point lateral to the inferior border of the nasal alar base. In addition, Nagase T, et al [14] and Hou D, et al [10] mentioned the possibility of detecting reversed blood flow in the facial artery by manual compression of the facial artery using ultrasonography intraoperatively.

This reversed blood flow from the cited authors lead to the conclusion that the angular artery is the continuation of the ophthalmic artery or that that the angular artery is not in direct continuation of the facial or the ophthalmic artery but connected with an anastomotic network. This anastomotic network may explain why after compressing the blood flow of the facial artery at the mandibular border, the blood flow persisted in two angular arteries that exhibited subsequent retrograde flow in our study.

Conclusion

The tendency for surgeons to attribute the blood supply of the nasolabial flap exclusively and automatically to the facial artery may explain misconceptions and the failure of truly axial nasolabial flaps.

Therefore, knowledge of the vascular anatomy of the artery and the accompanying vein is of major importance. Using color Doppler ultrasonography, the presence of the angular vessels, the symmetry on both sides, the relationship of the artery and vein, the diameter of the vessels and the direction of their flow can be imaged.

Color Doppler ultrasonography offers a valuable, uncomplicated and quick method to detect angular vessels and the direction of their flow even shortly before or during surgery.

References

- Lang J, Kopf, Teil A. Parent systems. Berlin: Springer Verlag; 2004. p. 543-548. German.
- Hollinshead WH. Anatomy for Surgeons: Volume I. Head and Neck. Philadelphia: JB Lippincott; 1982. p. 821-822.
- Dagregorio G, Baraer F, Darsonval V. Seven reconstructions of the orbital and periorbital region with a contralateral orbitonasolabial flap. Br J Plast Surg. 2005;58(7):940-3.
- Mitz V, Ricbourg B, Lassau JP. Facial branches of the facial artery in adults, typology, variations and respective cutaneous areas. Ann Chir Plast. 1973;18(4):339-50. French.
- Hagan WE, Walker LB. The nasolabial musculocutaneous flap: clinical and anatomical correlations. Laryngoscope. 1988;98(3):341-6.
- Hynes B, Boyd JB. The nasolabial flap. Axial or random? Arch Otolaryngol Head Neck Surg. 1988;114(12):1389-91.
- Zitelli JA. The nasolabial flap as a single-stage procedure. Arch Dermatol. 1990;126(11):1445-8.
- Zilinsky I, Alcalay J, Jacobs D, Tamir J, Winkler E, Haik J, et al. The versatility of the nasolabial flap enhanced by the delay procedure. Dermatol Surg. 2001;27(2):161-4.
- Kerem H, Bali U, Somnez E, Manavbasi YI, Yoleri L. The cranially based contralateral nasolabial flap for reconstruction of paranasal and periorbital surgical defects. J Plast Reconstr Aesthet Surg. 2014;67(5):655-61. doi: 10.1016/j.bjps.2014.01.027.
- Hou D, Fang L, Zhao Z, Zhou C, Yang M. Angular vessels as a new vascular pedicle of an island nasal chondromucosal flap: Anatomic study and clinical application. Exp Ther Med. 2013;5(3):751-756.
- Zhao Z, Li S, Xu J, Li Y, Huang W, Yang M, et al. Color doppler flow imaging of the facial artery and vein. Plast Reconstr Surg. 2000;106(6):1249-53.
- Zhao YP, Arijji Y, Gotoh M, Kurita K, Natsume N, Ma XC, et al. Color Doppler sonography of the facial artery in the anterior face. Oral Surg Oral Med Oral Pathol Oral Radiol Endod. 2002;93(2):195-201.

13. Shintani K, Takamatsu K, Uemura T et al. Planning digital artery perforators using color Doppler ultrasonography: A preliminary report. *J Plast Reconstr Aesthet Surg*. 2016;69(5):634-9. doi: 10.1016/j.bjps.2016.01.003.
14. Nagase T, Kobayashi S, Sekiya S, Ohmori K. Anatomic evaluation of the facial artery and vein using color Doppler ultrasonography. *Ann Plast Surg*. 1997;39(1):64-7.

***Corresponding author:** Gertrude M. Beer, Institute of Anatomy, Department of Macroscopic Anatomy, University Zurich, Irchel, Winterthurerstrasse 190, CH 8057 Zurich, Switzerland, Tel: 0041-442-020-400; Fax: 0041-442-020-410; E-mail: gertrude.beer@access.uzh.ch

Received Date: : April 06, 2016, **Accepted Date:** May 09, 2016, **Published Date:** May 19, 2016.

Copyright: © 2016 Beer GM, et al. This is an open access article distributed under the Creative Commons Attribution License, which permits unrestricted use, distribution, and reproduction in any medium, provided the original work is properly cited.

Citation: Beer GM, Bitschnau R, Manestar M (2016) Tracing the Blood Flow Direction of the Angular Artery and Vein by Color Doppler Ultrasonography. *J Oto Rec Surg* 2(1): 113.